ELSEVIER

Toxicology Letters 96,97 (1998) 309–318

Toxicology Letters

Tobacco smoke-induced alterations of cytokeratin expression in the rat nasal cavity following chronic inhalation of room-aged sidestream smoke

W.K. Schlage [a,*], H. Bülles [a], D. Friedrichs [a], M. Kuhn [a], A. Teredesai [a], P. Terpstra [b]

[a] *INBIFO Institut für biologische Forschung GmbH, Fuggerstr. 3, Köln 51149, Germany*
[b] *CRC Contract Research Center, Zaventem, Belgium*

Abstract

In a 12-month inhalation study on rats using room-aged sidestream smoke (RASS, 12 μg total particulate matter (TPM) l) as an experimental surrogate for environmental tobacco smoke (ETS), we investigated differentiation changes, i.e. altered cytokeratin (CK) expression, in the epithelial lining at nasal cavity level 1 (NL1) (anterior portion of nasal cavity), and their correlation with histomorphological changes. In addition to conventional histopathological examination, routine paraffin sections were immunohistologically stained for various rat CK and evaluated. Changes in CK expression were observed in the nonciliated respiratory epithelium of maxilloturbinate, lateral wall, and nasoturbinate: in basal cells, increase of CK14 and CK18 and decrease of CK15; in nonciliated columnar cells, increase of CK15 and CK19. These CK changes had histomorphological correlates, i.e. reserve cell hyperplasia and squamous metaplasia. CK expression changes were also seen at sites without histomorphological changes, e.g. enhanced expression of CK14, CK18 in ciliated cells at the dorsal meatus, and CK15 at the septum. Most of the CK expression changes seen after 1 year of RASS exposure resembled the changes previously seen after 8 days of exposure. © 1998 Elsevier Science Ireland Ltd. All rights reserved.

Keywords: Environmental tobacco smoke; Respiratory epithelium; Cytoskeleton; Cell differentiation; Immunohistochemistry; Histopathology

1. Introduction

Environmental tobacco smoke (ETS) is a highly diluted and aged mixture of sidestream smoke (SS) and exhaled mainstream smoke (MS) (First, 1985). It undergoes chemical and physical changes in composition due to aging, e.g. by contact with various surfaces over time (Eatough et al., 1989, 1990; Voncken et al., 1994). Major differences in concentration, phase distribution, and particle size of ETS in comparison to mainstream smoke and sidestream smoke have been described in the

* Corresponding author.

0378-4274/98/$19.00 © 1998 Elsevier Science Ireland Ltd. All rights reserved.
PII S0378-4274(98)00087-3

PM3006448309

Source: https://www.industrydocuments.ucsf.edu/docs/kljj0001

literature (Baker and Proctor, 1990; Rodgman, 1992; Martin et al., 1997). Room-aged sidestream smoke (RASS), which is used by us as an experimental surrogate for ETS, is diluted sidestream smoke aged in a controlled environment with noninert surfaces (Voncken et al., 1994). ETS was classified by the US Environmental Protection Agency (EPA) as a Class A (known human) carcinogen (Environmental Protection Agency, 1992) based on epidemiologic data and analogies to active cigarette smoking; however, no experimental data from chronic inhalation studies supporting the claimed biological plausibility of this classification have been published to date. The present paper is part of a 12-month inhalation study on rats that addresses the potential progression or development of histomorphological changes in the respiratory tract in combination with the investigation of additional mechanistic end points (Haussmann et al., 1998b). The high RASS concentration applied in this study (12 μg total particulate matter (TPM)/l) is similar to concentrations of a different ETS surrogate applied in short-term and subchronic inhalation studies on rats by others (Coggins et al., 1992, 1993; Brown et al., 1995). However, in comparison to real-life ETS concentrations, this RASS concentration is exaggerated: Particle mass concentrations in smoker-occupied residences showed average increases of up to 0.1 μg TPM/l and in restaurants of up to 1 μg TPM/l (Environmental Protection Agency, 1992).

In this paper, we report on the use of cytokeratin (CK) expression changes in the epithelial lining of the nasal cavity as an end point for changes in cell differentiation in a chronic inhalation study. CK intermediate filaments are the hallmarks of epithelial differentiation (Franke, 1993). The expression of various CK polypeptides in epithelial cells depends on the organ, the type of epithelium, and the differentiation status of the individual epithelial cell (for reviews, see Tseng et al., 1982; O'Guin et al., 1987; Sun, 1989; O'Guin et al., 1990; Kartenbeck and Franke, 1993). In human diagnostic histopathology, CK expression can be regarded as an established marker of neoplastic and nonneoplastic lesions (for reviews, see Ramaekers et al., 1988; Lane and Alexander, 1990; Fuchs and Weber, 1994; Miettinen, 1994; Nagle, 1994; Schaafsma and Ramaekers, 1994; McLean and Lane, 1995).

In our recently published paper on the use of this novel mechanistic end point in an 8-day inhalation study, we showed that CK expression changes may be a sensitive marker for cellular stress response (Schlage et al., 1998b). Short-term exposure to RASS resulted in CK expression changes which correlated in part with the observed histomorphological changes, i.e. slight to moderate reserve cell hyperplasia and squamous metaplasia of the nonciliated respiratory epithelium at nasal cavity level 1 (NL1). Such histomorphological changes were shown by us and others to be fully reversible in acute and subchronic cigarette smoke inhalation studies (Coggins et al., 1993; Maples et al., 1993; Ayres et al., 1995; Tesfaigzi et al., 1996). It is not known, however, whether there are additional progressive histomorphological and CK expression changes after 12 months of exposure. Therefore, the objectives of the present investigation were: to determine cell differentiation changes, seen as altered CK expression, in rat nasal epithelia[1] following chronic RASS inhalation; to correlate these changes with histomorphological changes; and to compare the changes after chronic inhalation with the early adaptive changes after short-term inhalation.

2. Materials and methods

2.1. General remarks

The present investigation was part of a larger 1-year inhalation study including different concentrations and inhalation modes and additional mechanistic end points. Details concerning experimental design, animals, RASS generation and analytical characterization, inhalation exposure, and histopathological evaluation will be published elsewhere (Haussmann et al., 1998b).

[1] CK expression changes at nasal cavity level 2 (NL2) and in the lower respiratory tract will be addressed in a forthcoming paper.

PM3006448310

Source: https://www.industrydocuments.ucsf.edu/docs/kljj0001

2.2. Experimental design

Female rats (eight per group) were whole-body exposed to RASS at a concentration of 12 μg TPM l or to filtered, conditioned fresh air (sham-exposed group) for 12 h/day, 5 days/week, for 12 months. The study was performed in compliance with the American Association for Laboratory Animal Science policy on the Humane Care and Use of Laboratory Animals (1991).

2.3. Experimental animals

A total of 16 female outbred Wistar rats (Crl:(WI)WU BR), bred under specified pathogen-free conditions, were obtained at 5 weeks of age from Charles River (Sulzfeld, Germany). The rats were barrier-maintained in an animal laboratory unit with controlled hygienic conditions. The rats were housed (two per cage) in stainless steel wire mesh cages which were mounted above stainless steel excretion pans. The cages were located in exposure chambers, 24 cages per chamber, during both exposure and nonexposure periods. Temperature was maintained at 22 ± 1°C, relative humidity at 62 ± 9%. The light/dark cycle was 10 and 14 h starting at 7:00 am. Water from sterilized drinking bottles and autoclaved, fortified diet (Eggersmann KG, Rinteln, FRG) were provided ad libitum, but not during exposure. The laboratory air was filtered (Class S) and conditioned. Results of the chemical analysis of the food and water were in compliance with the NTP guidelines National Toxicology Program (1991).

2.4. RASS generation and inhalation exposure

Fresh sidestream smoke (University of Kentucky standard reference cigarette 1R4F, INBIFO 30-port smoking machine) was diluted with conditioned, fresh air and continuously conveyed into an aging room (2 air changes per h, mean RASS age 30 min) with noninert surfaces as previously described (Voncken et al., 1994; Haussmann et al., 1998a). During nonexposure periods, fresh air was circulated through the room.

RASS was drawn from the aging room (volume 28 m^3) through the whole body exposure chamber (volume approximately 0.8 m^3). Two groups of eight female rats were exposed to filtered, conditioned air (sham exposed control group) or to RASS having the following mean concentrations: TPM 11.9 ± 0.6 μg/l, carbon monoxide 51 ± 2 ppm, nicotine 1.95 ± 0.57 μg/l.

2.5. Necropsy and histopathology

The rats were killed by exsanguination via the abdominal aorta and vena cava under deep pentobarbital anaesthesia. The nasal cavity was prepared as described (Young, 1981), fixed with buffered formalin solution and decalcified in 5% nitric acid. It was then trimmed to obtain a slice at the defined cross-sectional level, nasal cavity level I, immediately posterior to the upper incisor teeth (Young, 1981), dehydrated and embedded in Paraplast. Approximately 15 serial sections at 5 μm thickness were obtained and mounted on adhesive slides (Super-Frost Plus, Menzel Glas, Braunschweig, FRG). The first section of each series was stained with hematoxylin and eosin (HE), and the second with alcian blue/periodic acid Schiff's reagent (AB PAS), for histopathological examination. The other sections of the series were used for immunostaining with the various antibodies. All histopathological slides were read by a veterinary pathologist. All pathological findings were scored according to a defined severity scale from 0 (no visible effects) to 5 (marked effects) (see Table 2). Mean severity scores were calculated based on all rats in a group.

2.6. Immunohistological procedures and evaluation

Details of the immunostaining procedure and the individual scoring have been published (Schlage et al., 1996, 1998a). In brief, the paraffin sections were dewaxed and immunostained following antigen retrieval by protease or microwave treatment using an antibody panel with defined specificity for rat CK (Table 1). In a modification of our previously published method, the slides were stained using immunochemicals of

PM3006448311

Source: https://www.industrydocuments.ucsf.edu/docs/kljj0001

Table 1
Antibody panel for the detection of rat cytokeratins in paraffin sections

Name	Supplier	Specificity		Dilution	Unmasking
		Human CK (a)	Rat CK (b)		
Ks 18.04	Progen	18	18	1:2000	Protease
LE 002	BioGenex	14	14	1:1000	Microwave
CK-E3	Sigma	17	19	1:4000	Protease
Ks 13.1	Progen	13, (14,16)	13, (15)	1:50	Protease
Ks 8.12	Sigma	13, (15), 16	15, 13	1:50	Protease
6B10	Sigma	4	4	1:100	Microwave
Ks 8.60	Sigma	(1), 10, 11	1, 10/11 (c)	1:1000 (d)	Microwave
OV-TL12.30	BioGenex	7	7	1:6000	Protease
PCK 26	Sigma	1, 5, 6, 8	1, 5, 6, 8	1:5000	Various (e)

Remarks: (a) as given by supplier and literature; (b) as determined by immunoblotting; (c) 10/11: without 2D electrophoresis, it was impossible to distinguish between CK10 and CK11; (d) affinity purified; (e) performs equally well with protease and microwave.

the Optimized Staining System (Dako, Hamburg, FRG), which were originally designed for machine staining. Due to the higher sensitivity obtained, it was necessary to readjust the dilution ratios of the CK antibodies (Table 1). For evaluation, the epithelia present on the slides were divided into defined evaluation compartments (Figs. 1 and 2, Table 3) and individual scores were given for each distinguishable cell type within each compartment, by using 4-stage scores for the staining intensity and the relative distribution of the stained versus the unstained cells of this type (Schlage et al., 1996).

All immunohistological evaluations were reviewed by a veterinary pathologist. For the statistical comparison between the RASS-exposed and the sham-exposed group, the generalized Cochran–Mantel–Haenszel test (Koch and Edwards, 1988) was used; the score values for intensity and distribution were tested separately and in combination. The staining of metaplastic cells was evaluated separately; a statistical comparison was not done (lack of metaplasia in untreated control rats). In the present publication, only the statistically significant CK staining differences between RASS-exposed and control rats are shown. For the complete CK expression pattern in the rat nasal cavity, refer to our previously published papers (Schlage et al., 1996, 1998a). Microphotographic images were recorded using a 1/2 inch 3-chip CCD video camera (Sony DXC930P) and digitized using the Kontron KS300 image analysis system (Zeiss, Jena).

3. Results and discussion

3.1. CK expression changes with histomorphological correlates

The histopathological examination of the HE-stained sections revealed in all exposed rats slight or slight/moderate reserve cell hyperplasia and in five of eight rats slight or slight/moderate squamous metaplasia of the nonciliated respiratory epithelium (Table 2). In one exposed rat, moderate goblet cell hyperplasia was diagnosed in the respiratory epithelium of the septum. In the epithelial areas with these histomorphological changes, i.e. maxilloturbinate, lateral wall, and nasoturbinate, we observed statistically significant CK expression changes for CK7, CK14, CK15, CK18, CK19 as shown in Table 3 (shaded area). In the basal cells, staining was increased for CK14 and CK18 and decreased for CK19. In the nonciliated cells without squamous metaplasia, staining was increased for CK14, CK18, and CK19 and decreased for CK7. In metaplastic cells, CK15 was frequently expressed; CK14 and CK19 less frequently and only focally; and CK1, 10/11, CK7, CK13, and CK18 focally in single rats only. In bronchial and other pseudostratified epithelia, e.g. prostate (Hsieh et al., 1992), CK15 is normally expressed in basal cells (reviewed by Schaafsma and Ramaekers, 1994). Its enhanced and suprabasal expression in squamous metaplastic

PM3006448312

Source: https://www.industrydocuments.ucsf.edu/docs/kljj0001

Table 2
Histopathological findings (frequency per group and mean score) at NL1 following exposure to RASS for 1 year

Finding		Reserve cell hyperplasia		Squamous metaplasia	
		Frequency (%)			
Severity	Score	Sham	RASS	Sham	RASS
None	0	100 (100)	0 (0)	100 (100)	37.5 (0)
Slight	1	0 (0)	12.5 (0)	0 (0)	25.0 (0)
Slight moderate	2	0 (0)	87.5 (100)	0 (0)	37.5 (100)
Moderate	3	0 (0)	0 (0)	0 (0)	0 (0)
Moderate marked	4	0 (0)	0 (0)	0 (0)	0 (0)
Marked	5	0 (0)	0 (0)	0 (0)	0 (0)
Mean score		0 (0)	1.9 (2.0)	0 (0)	1.0 (2.0)

Remarks: results for 8D exposure in parenthesis

epithelium and in intraepithelial neoplastic lesions has been reported for human tracheobronchial (Leube and Rustad, 1991), mammary (Wetzels et al., 1991), and cervical epithelium (Smedts et al., 1993). The suprabasal metaplastic staining patterns found for CK18 and CK19 at NL1 are also similar to those observed in human tracheobronchial squamous metaplasia (Leube and Rustad, 1991), whereas these authors reported abundant expression of CK4 and CK13 (not seen at NL1) and no expression of CK7 and CK14 (focal at NL1).

3.2. CK expression changes without histomorphological correlates

Additional CK expression changes were seen in epithelial areas without visible histomorphological (HE-staining) changes (Table 3). In the ventral meatus, staining was decreased for CK13 in suprabasal cells of the stratified squamous epithelium and increased for CK19 in the transitional epithelial cells which were frequently seen as a small group of cuboidal, nonciliated cells between the squamous epithelium of the ventral meatus and the ciliated epithelium at the base of maxilloturbinate. CK expression was also changed in the ciliated respiratory epithelium: in the ventral part of the septum and the base of maxilloturbinate, the staining of basal cells was increased for CK7 and decreased for CK15. In the middle part of the septum, the staining of basal cells was decreased for both CK7 and CK15, while staining of ciliated cells for CK15 was increased. In the dorsal part of the septum and the ciliated epithelium lining the medial aspect of the nasoturbinate, staining of basal cells was increased for CK7 and CK18, and staining of ciliated cells was increased for CK14 and CK18. In cells of the stratified squamous epithelium, which was not always present in the nasolacrimal duct, decreased staining was seen for CK14. The staining for CK4 was negative in all nasal cavity epithelia of RASS-exposed and control rats.

3.3. Long-term versus short-term exposure

The histomorphological changes seen in the nonciliated respiratory epithelium at NL1 after 1 year of RASS exposure in comparison to those seen after 8 days of exposure (Table 2) were similar in localization and severity, particularly with regard to reserve cell hyperplasia. For squamous metaplasia, the mean score was slightly lower after 1 year: 1.0 for 1 year and 2.0 for 8 days. The site and severity of our histomorphological findings is consistent with the published data on the effects of short-term exposure to a different ETS model at comparable TPM concentrations (Coggins et al., 1992, 1993; Brown et al., 1995). It has been demonstrated that such histomorphological changes are fully reversible even after subchronic inhalation (Coggins et al., 1993; Teredesai and Prühs, 1994; Ayres et al., 1995;

PM3006448313

Source: https://www.industrydocuments.ucsf.edu/docs/kljj0001

Haussmann et al., 1998a) or after inhalation exposure to mainstream smoke at concentrations as high as 250 mg TPM m^3 (Maples et al., 1993; Tesfaigzi et al., 1996). These changes can, therefore, be regarded as adaptive responses to irritant stress (Burger et al., 1989; Witschi et al., 1995). Whether these changes are also reversible after chronic exposure to RASS has not yet been demonstrated.

The pattern of CK expression changes concomitant with reserve cell hyperplasia and squamous metaplasia in the nonciliated respiratory epithelium after 1 year of RASS inhalation largely paralleled our results from the 8-day inhalation study for the basal cell markers CK14 and CK15, and for the cornified squamous epithelial marker CK1, 10/11. The following differences between short-term and long-term inhalation were seen: expression of the 'simple epithelial' marker CK18 in basal cells of the lateral wall and nasoturbinate was decreased after short-term inhalation; but after chronic inhalation it was increased and also expressed in metaplastic cells. The decreased staining for CK19 in basal cells of the maxilloturbinate and lateral wall and its increased staining in the nonciliated cells of the nasoturbinate after 1 year was not seen after 8 days. Unique to the 1-year inhalation was also the focal expression of the 'noncornified squamous epithelial' marker, CK13, and of the 'simple epithelial' markers CK7, CK18, and CK19, mostly in isolated metaplastic cells (except CK19). With regard to the adnexes of the nasal cavity, the enhanced CK19 expression in basal cells of the

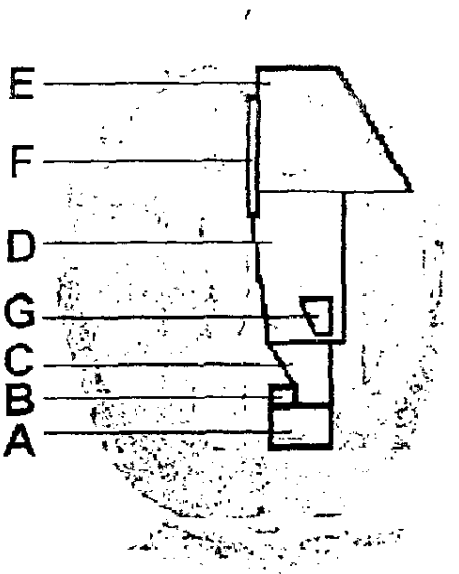

Fig. 1. Evaluation areas at nasal cavity, level I. A, ventral meatus; B, vomeronasal organ; C, respiratory region, lower part (septum, maxilloturbinate); D, respiratory region, middle part (septum, maxilloturbinate, lateral wall); E, respiratory region, upper part (lateral wall, nasoturbinate, septum); F, submucosal glands; G, nasolacrimal duct.



Fig. 2. CK expression in squamous metaplasia of the nonciliated respiratory epithelium. (a) CK 19, nasoturbinate CK 14, lateral wall; (b) CK 14, maxilloturbinate; (c) CK 15, maxilloturbinate (same site as b). The dots in the diagram (upper left) indicate the localization of the image fields. Bar: 10 μm.

PM3006448314

Source: https://www.industrydocuments.ucsf.edu/docs/kljj0001

Table 3
Changes of rat CK expression following RASS inhalation at nasal cavity level I

Area (Fig. 1)	A		C		D				E				G
Site	ventral meatus		maxilloturbinate, septum (ventral parts)		maxilloturbinate, lateral wall (ventral part)		septum (middle part)		nasoturbinate (lateral aspect), lateral wall (dorsal part)		nasoturbinate, (medial aspect), septum (dorsal part)		naso-lacrimal duct
Epithelium	stratified squamous	transitional	respir., ciliated		respir., cuboidal		respir., ciliated		respir., cuboidal		respir., ciliated		stratified squamous
Cell type	suprabasal	all cells	basal	ciliated	basal	nonciliated	basal	ciliated	basal	nonciliated	basal	ciliated	squamous
CK1,10(11)						(a)				(a)			
CK7			↑			↓↓,(a)	↓			(a)			[↓↓]
CK13	↓					(a)				(a)			
CK14					[↑↑]	↑↑, (a)			↑↑	(a)		↑	↓
CK15			↓			(a)	↓	↑		↑, (a)			
CK18					[↓]				↑	(a)	↑	↑	
CK19		↑			↓	(a)				↑, (a)			

Remarks: statistically significant differences between RASS and sham-exposed rats (CMH-test): ↑, ↓: $P<0.05$; ↓↓, ↑↑: $P<0.01$. (a) Staining of cells in squamous metaplasia; cell type not present in unexposed control rats. *Shaded*, changes with histopathological correlates. *Boxes*, changes corresponding to those after 8-day inhalation period. *Brackets*, changes observed after 8-day inhalation period only.

PM3006448315

Source: https://www.industrydocuments.ucsf.edu/docs/kljj0001

nonsensory epithelium seen after 8 days of inhalation was not observed after 1 year; also not observed was the short-term exposure related decrease in CK7 in squamous cells of the nasolacrimal duct, however, a decrease in CK14 in these cells was seen after chronic inhalation.

With regard to epithelial compartments without histomorphological changes, the decreased staining for CK13 in suprabasal cells of the stratified squamous epithelium of the ventral meatus after 1 year of exposure parallels that observed after 8 days. The same holds true for CK15 in the basal cells of the ciliated respiratory epithelium of the nasal septum and the base of the maxilloturbinate. The increase of CK14 and CK15 in ciliated cells and of CK18 in basal and ciliated cells at the septum, however, was seen after chronic inhalation only. The changes in CK7 in the basal cells of the ciliated epithelium of the septum and in CK19 in the transitional epithelium of the ventral meatus were also observed at NL1 after chronic inhalation only.

3.4. Summary, conclusion, and outlook

Following RASS inhalation for one year, a variety of CK expression changes were seen that correlated in part with typical histomorphological changes, i.e. reserve cell hyperplasia and squamous metaplasia of the nonciliated respiratory epithelium in the anterior rat nasal cavity. CK expression changes were also seen in epithelial compartments without detectable histomorphological changes, e.g. in the ciliated respiratory epithelium. With minor exceptions, all the CK expression changes seen after 8 days of inhalation persisted in the 1 year inhalation study. In addition to the changes seen after 8-day exposure, enhanced CK expression was seen notably for CK18 in basal cells and for CK7, CK13, CK18, CK19 in metaplastic cells of the nonciliated respiratory epithelium and for CK14, CK15, and CK18 in cells of the ciliated respiratory epithelium.

In conclusion, these results show the usefulness of CK expression changes as a sensitive end point for altered epithelial cell differentiation in inhalation studies. Most of the CK expression changes seen in the early adaptive phase after short-term inhalation were also observed after chronic inhalation. Moreover, additional CK expression changes were seen after chronic inhalation, although the severity and frequency of histomorphological changes was decreased rather than increased. Whether these CK expression changes are fully reversible or can serve as intermediate biomarkers (Henderson, 1995) for irreversible changes in the respiratory epithelium, can only be addressed in a prolonged (> 1 year) chronic inhalation study including a recovery period.

Acknowledgements

This work was sponsored by Philip Morris (USA). The authors wish to thank L. Conroy-Schneider for critically reviewing the manuscript.

References

Ayres, P.H., McKarns, S.C., Coggins, C.R.E., Doolittle, D.J., Sagartz, J.E., Payne, V.M., Mosberg, A.T., 1995. Replicative DNA synthesis in tissues of the rat exposed to aged and diluted sidestream smoke. Inhal. Toxicol. 7, 1225–1246.

Baker, R.R., Proctor, C.J., 1990. The origins and properties of environmental tobacco smoke. Environ. Int. 16, 231–245.

Brown, B.G., Bombick, B.R., McKarns, S.C., Lee, C.K., Ayres, P.H., Doolittle, D.J., 1995. Molecular toxicology endpoints in rodent inhalation studies. Exp. Toxicol. Pathol. 47, 183–191.

Burger, G.T., Renne, R.A., Sagartz, J.W., Ayres, P.H., Coggins, C.R.E., Mosberg, A.T., Hayes, A.W., 1989. Histologic changes in the respiratory tract induced by inhalation of xenobiotics: physiologic adaptation or toxicity? Toxicol. Appl. Pharmacol. 101, 521–541.

Coggins, C.R.E., Ayres, P.H., Mosberg, A.T., Ogden, M.W., Sagartz, J.W., Hayes, A.W., 1992. Fourteen-day inhalation study in rats, using aged and diluted sidestream smoke from a reference cigarette. I. Inhalation toxicology and histopathology. Fundam. Appl. Toxicol. 19, 133–140.

Coggins, C.R.E., Ayres, P.H., Mosberg, A.T., Sagartz, J.W., Hayes, A.W., 1993. Subchronic inhalation study in rats using aged and diluted sidestream smoke from a reference cigarette. Inhal. Toxicol. 5, 77–96.

Eatough, D.J., Benner, C.L., Bayona, J.M., Richards, G., Lamb, J.D., Lee, M.L., Lewis, E.A., Hansen, L.D., 1989. Chemical composition of environmental tobacco smoke. 1. Gas phase acids and bases. Environ. Sci. Technol. 23, 679–687.

Eatough, D.J., Hansen, L.D., Lewis, E.A., 1990. The chemical characterization of environmental tobacco smoke. Environ. Technol. 11, 1071–1085.

PM3006448316

Source: https://www.industrydocuments.ucsf.edu/docs/kljj0001

Environmental Protection Agency (EPA) (Ed.), 1992. Respiratory Health Effects of Passive Smoking: Lung Cancer and Other Disorders. Office of Research and Development, Washington, DC.

First, M., 1985. Constituents of sidestream and mainstream tobacco smoke and markers to quantify exposure to them. In: Gammage, R.B., Kaye, S.V. (Eds.), Indoor Air and Human Health. Lewis, Chelsea, MI, pp. 195–203.

Franke, W.W., 1993. The intermediate filaments and associated proteins. In: Kreis, T., Vale, R. (Eds.), Guidebook to the Cytoskeletal and Motor Proteins. Oxford University Press, Oxford, pp. 137–143.

Fuchs, E., Weber, K., 1994. Intermediate filaments: structure, dynamics, function, and disease. Ann. Rev. Biochem. 63, 345–382.

Haussmann, H.J., Anskeit, E., Becker, D., Kuhl, P., Stinn, W., Teredesai, A., Voncken, P., Walk, R.A., 1998a. Comparison of fresh and room-aged cigarette sidestream smoke in a subchronic inhalation study on rats. Toxicol. Sciences 41, 100–116.

Haussmann, H.J., Gerstenberg, B., Göcke, W., Kuhl, P., Schepers, G., Stabbert, R., Stinn, W., Teredesai, A., Tewes, F., Anskeit, E., Terpstra, P., 1998b. Twelve-month inhalation study study on room-aged cigarette sidestream smoke in rats. Inhal. Toxicol. (in press).

Henderson, R.F., 1995. Strategies for use of biological markers of exposure. Toxicol. Lett. 82/83, 379–383.

Hsieh, J.T., Zhau, H.E., Wang, X.H., Liew, C.C., Chung, L.W.K., 1992. Regulation of basal and luminal cell-specific cytokeratin expression in rat accessory sex organs. Evidence for a new class of androgen-repressed genes and insight into their pairwise control. J. Biol. Chem. 267, 2303–2310.

Kartenbeck, J., Franke, W.W., 1993. Cytokeratins. In: Kreis, T., Vale, R. (Eds.), Guidebook to the Cytoskeletal and Motor Proteins. Oxford University Press, Oxford, pp. 145–148.

Koch, G.G., Edwards, E., 1988. Clinical efficiency trials with categorial data. In: Pearce, K.E. (Ed.), Biopharmaceutical Statistics for Drug Development. Marcel Dekker, New York, pp. 403–457.

Lane, E.B., Alexander, C.M., 1990. Use of keratin antibodies in tumor diagnosis. Semin. Cancer Biol. 1, 165–179.

Leube, R.E., Rustad, T.J., 1991. Squamous cell metaplasia in human lung: molecular characteristics of epithelial stratification. Virchows Arch. B. Cell Pathol. 61, 227–253.

Maples, K.R., Nikula, K.J., Chen, B.T., Finch, G.L., Griffith, W.C., Harkema, J.R., 1993. Effects of cigarette smoke on the glutathione status of the upper and lower respiratory tract of rats. Inhal. Toxicol. 5, 389–401.

Martin, P., Heavner, D.L., Nelson, P.R., Maiolo, K.C., Risner, C.H., Simmons, P.S., Morgan, W.T., Ogden, M.W., 1997. Environmental tobacco smoke (ETS): a market cigarette study. Environ. Int. 23, 75–90.

McLean, W.H.I., Lane, E.B., 1995. Intermediate filaments in disease. Curr. Opin. Cell Biol. 7, 118–125.

Miettinen, M., 1994. Keratin immunohistochemistry: update of applications and pitfalls. Pathol. Annu. 28, 113–143.

Nagle, R.B., 1994. A review of intermediate filament biology and their use in pathologic diagnosis. Mol. Biol. Rep. 19, 5–21.

National Toxicology Program (NTP), 1991. Specifications for the conduct of studies to evaluate the toxic and carcinogenic potential of chemical, biological, and physical agents in laboratory animals for the National Toxicology Program (NTP). In: National Toxicology Program (NTP) (Ed.), Annual Report on Carcinogens (6th). Technical Resources Inc., Rockville, MD, pp. 1–1026.

O'Guin, W.M., Galvin, S., Schermer, A., Sun, T.T., 1987. Patterns of keratin expression define distinct pathways of epithelial development and differentiation. Curr. Top. Dev. Biol. 22, 97–125.

O'Guin, W.M., Schermer, A., Lynch, M., Sun, T.T., 1990. Differentiation-specific expression of keratin pairs. In: Goldman, R.D., Steinert, P.M. (Eds.), Cellular and Molecular Biology of Intermediate Filaments. Plenum, New York, pp. 301–334.

Ramaekers, F.C.S., Vooijs, G.P., Huijsmans, A.C.L.M., Salet-Van den Pol, M.R.J., 1988. Immunohistochemistry as an aid in diagnostic histopathology. In: DeLellis, R.A. (Ed.), Advances in Immunohistochemistry. Raven, New York, pp. 133–163.

Rodgman, A., 1992. Environmental tobacco smoke. Regul. Toxicol. Pharmacol. 16, 223–244.

Schaafsma, H.E., Ramaekers, F.C.S., 1994. Cytokeratin subtyping in normal and neoplastic epithelium: basic principles and diagnostic applications. Pathol. Annu. 29, 21–62.

Schlage, W.K., Bülles, H., Friedrichs, D., Teredesai, A., 1996. Cytokeratin patterns of epithelial cells of the rat nasal cavity in vivo and in vitro. Toxicol. Lett. 88, 65–73.

Schlage W.K., Bülles, H., Friedrichs, D., Kuhn, M., Teredesai, A., 1998a. Cytokeratin expression patterns in the rat respiratory tract as markers of epithelial differentiation in inhalation toxicology. I. Determination of normal cytokeratin expression patterns in nose, larynx, trachea and lung. Toxicol. Pathol. 26, 324–343.

Schlage W.K., Bülles, H., Friedrichs, D., Kuhn, M., Teredesai, A., Terpstra, P.M., 1998b. Cytokeratin expression patterns in the rat respiratory tract as markers of epithelial differentiation in inhalation toxicology. II. Changes in cytokeratin expression patterns following 8-day exposure to room-aged cigarette sidestream smoke. Toxicol. Pathol. 26, 344–360.

Smedts, F., Ramaekers, F., Leube, R.E., Keijser, K., Link, M., Vooijs, P., 1993. Expression of keratins 1, 6, 15, 16, and 20 in normal cervical epithelium, squamous metaplasia, cervical intraepithelial neoplasia, and cervical carcinoma. Am. J. Pathol. 142, 403–412.

Sun, T.-T., 1989. Pathways of keratinocyte differentiation. In: Osborn, M., Weber, K. (Eds.), Cytoskeletal proteins in tumor diagnosis. Cold Spring Harbor Laboratory, Cold Spring Harbor, pp. 121–126.

Teredesai, A., Prühs, D., 1994. Histopathological findings in the rat and hamster respiratory tract in a 90-day inhalation study using fresh sidestream smoke of the standard reference cigarette 2R1. In: Mohr, U. (Ed.), Toxic and Carcinogenic Effects of Solid Particles in the Respiratory Tract. ILSI Press, Washington, DC, pp. 629–635.

PM3006448317

Source: https://www.industrydocuments.ucsf.edu/docs/kljj0001

Teslaigzi, J., Thing, J., Hotchkiss, J.A., Harkema, J.R., Wright, P.S., 1996. A small proline-rich protein, SPRR1, is up-regulated early during tobacco smoke-induced squamous metaplasia in rat nasal epithelia. Am. J. Respir. Cell Mol. Biol. 14, 478–486.

Tseng, S.C.G., Jarvinen, M.J., Nelson, W.G., Huang, J.W., Woodcock-Mitchell, J., Sun, T.T., 1982. Correlation of specific keratins with different types of epithelial differentiation: monoclonal antibody studies. Cell 30, 361–372.

Voncken, P., Stinn, W., Haussmann, H.-J., Anskeit, E., 1994. Influence of aging and surface contact on the composition of cigarette sidestream smoke. Models for environmental tobacco smoke. In: Mohr, U. (Ed.), Toxic and Carcinogenic Effects of Solid Particles in the Respiratory Tract. ILSI Press, Washington, DC, pp. 637–641.

Wetzels, R.H.W., Kuijpers, H.J.H., Lane, E.B., Troyanovsky, S.M., Holland, R., van Haelst, U.J.G.M., Ramaekers, F.C.S., 1991. Basal cell-specific and hyperproliferation-related keratins in human breast cancer. Am. J. Pathol. 138, 751–763.

Witschi, H., Oreffo, V.I.C., Pinkerton, K.E., 1995. Six-month exposure of strain A J mice to cigarette sidestream smoke: cell kinetics and lung tumor data. Fundam. Appl. Toxicol. 26, 32–40.

Young, J.T., 1981. Histopathologic examination of the rat nasal cavity. Fundam. Appl. Toxicol. 1, 309–312.

PM3006448318

Source: https://www.industrydocuments.ucsf.edu/docs/kljj0001